


**PATIENT**

Cali Clapperton

**PRESENTING CLINICAL SIGNS**

History: Syncopal episodes.

**SPECIES**

Feline

**RADIOGRAPHIC FINDINGS** \*NOTE: Images submitted for supplemental cardiac information only.  
 Cardiomegaly. Concern for impending CHF.

**BREED**

DLH

**ECHOCARDIOGRAM FINDINGS**

2D, m-mode, color flow and doppler imaging is available. The left ventricular wall is normal in dimension. The LV is mildly dilated. There is a diffusely hyperechoic endocardium consistent with fibrosis. The papillary muscles are remodeled. Systolic function is adequate. The left atrium is severely dilated and bulbous in appearance. Smoke seen in the LA. The left auricle is dilated as well. Mild to moderate central mitral regurgitation. The right atrium is moderately dilated. The right ventricle appears largely normal. Trace tricuspid regurgitation. Blood flow through both the LVOT and RVOT are both low normal in velocity. Scant pericardial effusion. No pleural effusion. No obvious cardiac tumors.

**AGE**

12 years

**CARDIAC CHART**
**WEIGHT**

10lbs

FELINE CARDIAC PARAMETERS	BODY WEIGHT (kg)	HR (BPM)	IVSd (cm) (Moise, Pipers)	LVIDd (cm) (Moise, Pipers)	LVWd (cm) (Moise, Pipers)	FS (%)	EF (%)
NORMAL PARAMETER	-----	150-240	0.35-0.55	<2 (mean 1.5)	3.5-0.55	35-67	80-100
PATIENT	4.5	210	0.50	1.72	0.46	44	79
FELINE CARDIAC PARAMETERS	LA/AO (Boon)	LA/AO HEART BASE (Swe) (Abbott)	LA 2D short axis Base view (cm) (Abbott)	LVOT VEL (m/s)	RVOT VEL (m/s)	E max (m/s)	
NORMAL	<1.5	<1.3	<1.2	<1.6	<1.3	<0.9	
PATIENT	2.2	2.0	1.8	0.6	0.7	NM	
*Note: All measurements based upon multi-modal images and methods. An average value is reported. Adapted from June Boon, Veterinary Echocardiography, 1998 Abbott J & MacLean H JVIM 2006;20: 111-119, Moise et al. Am J Vet Res 47:1476, 1986. Pipers et al. Am J Vet Res 40:882, 1979.							

**INTERPRETED BY**

 Maggie Machen Lamy,  
 DVM DACVIM  
 (Cardiology)

**IMAGING PERFORMED BY**

Kelly Reschny, RVT

**HOSPITAL NAME**

 Hawkins Animal  
 Hospital

**REFERRING VET**

Dr. Hawkins

**INVOICE**

28396

**DATE**

1/17/23

**INTERPRETATION OF THE FINDINGS & FURTHER RECOMMENDATIONS**

The finding of biatrial enlargement in the face of normal LV wall thickness is most consistent with Unclassified Cardiomyopathy (UCM); however, some prior infectious or inflammatory insult to the myocardium cannot be definitively ruled out. There is also significant LV remodeling and fibrosis which indicates significant diastolic dysfunction. No significant hypertrophic is noted ruling out typical hypertrophic disease. MR and TR are noted which are likely secondary to annular stretch, although underlying valve disease is also possible. Regardless of categorical classification, the finding of this degree of atrial dilation and smoke is concerning for progression in the future and full cardiac supportive medications are recommended as below. Scant pericardial effusion suggests early decompensation, and is likely the cause of reported syncope. No additional issues are identified.



**PATIENT**

Cali Clapperton

Prognosis is guarded to poor long term even without reported symptoms. There will always be risk for progression to CHF, malignant arrhythmias, development of blood clots and/or sudden death in the future. Monitoring of sleeping breathing rates at home is recommended as the best way to screen for progression to CHF at home.

**SPECIES**

Feline

**Elective anesthesia, fluid or steroid therapy should be avoided in this case due to high risk for complication.**

**BREED**

DLH

**PLAN**

Screening BP. Institute blood thinner Clopidogrel (Plavix) 75mg tablets; give ¼ tab orally once daily (NOTE: this medication is very bitter on the cut edges). Institute Pimobendan (off label use) 1.25mg PO q12h. Institute Lasix 1mg/kg q12h.

**SEX**

Female Spayed

Recheck renal values in 10-14 days to ensure tolerance of medications, then every 3-4 months lifelong. If eating well at home and BP >130mmHg, consider addition of vasodilator ACE-I (benazepril or enalapril) 0.5mg/kg PO q12h.

**AGE**

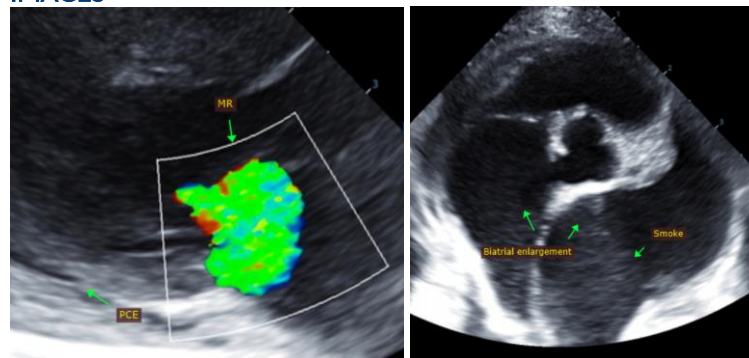
12 years

A recheck echocardiogram is recommended in 6 months to assess for progression, sooner if clinical issues arise.

**WEIGHT**

10lbs

**IMAGES**



**INTERPRETED BY**

Maggie Machen Lamy,  
DVM DACVIM  
(Cardiology)

The information and recommendations provided are based on the images presented by the referring veterinarian. No evaluation can be communicated regarding pathology that was not visible in the image/video clips provided.

**IMAGING PERFORMED BY**

Kelly Reschny, RVT

**HOSPITAL NAME**

Hawkins Animal  
Hospital

Thank you for this referral. This report was generated using transcription software, and minor dictation errors may be present. If the clinical or image interpretation does not parallel your findings or if I can be of any further assistance, please contact me.

**REFERRING VET**

Dr. Hawkins

Maggie Machen Lamy, DVM  
Diplomate of the American College of Veterinary Internal Medicine (Cardiology)  
info@sonopath.com

**INVOICE**

28396

**DATE**

1/17/23